

A Professional Courtesy of:

A. K. Bobby Mallik, D.M.D.

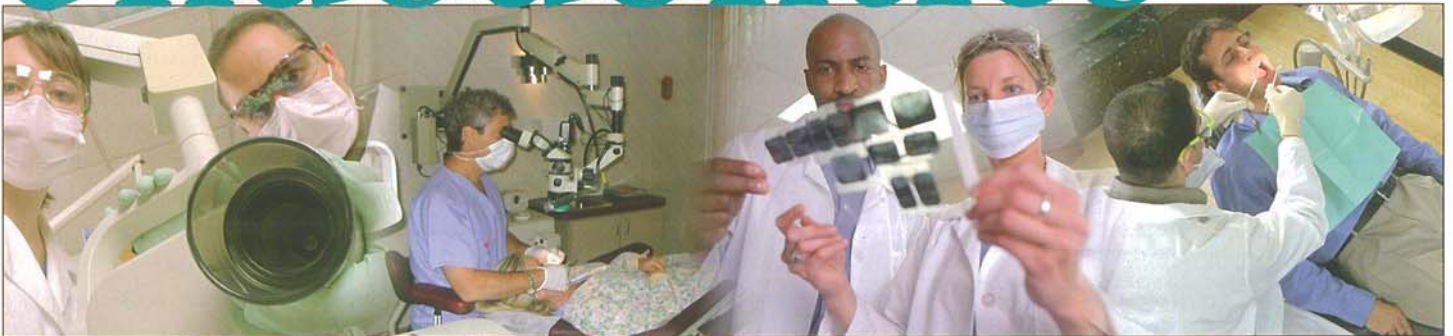3719-B University Commons
Durham, North Carolina 27707

919-493-5332

www.durhamendo.com

Practice Limited to Endodontics

update on endodontics™



Endodontic Disease and Coronary Heart Disease: Is There a Connection?

It has been shown that certain people, in response to the gram-negative anaerobic bacteria found in periodontal disease, may produce an overabundance of localized and/or systemic inflammatory mediators, possibly contributing to vascular damage and cardiovascular events. It is therefore possible that endodontic infections could be related to cardiovascular conditions because of the prevalence of gram-negative anaerobes in endodontic infections. Additionally, the cytokine production that exists in inflamed pulpal and periapical tissues may also contribute to heart disease.

Caplan et al from the University of Iowa conducted a cross-sectional study to evaluate the relationship between self-reported history of endodontic treatment (ET) and prevalent coronary heart disease (CHD) among dentate participants in the Atherosclerosis Risk in Communities (ARIC) Study. An ongoing longitudinal population-based investigation sponsored by the National Heart, Lung, and Blood Institute, ARIC was designed to assess determinants of atherosclerosis and to describe its effect on community mortality and morbidity. The authors hypothesized that the odds of prevalent CHD would be higher among participants with a greater self-reported history of ET.

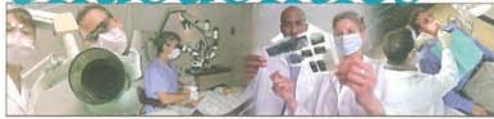Among the 6651 participants, 395 (5.9%) had prevalent CHD; their median number of teeth was 24. Of the total number of participants analyzed,

Inside this issue:

Spring 2010

- Chlorhexidine Gluconate for Intracanal Healing
- Calcium Hydroxide and pH Levels on Root Surfaces
- Splinting Times for Replanted Avulsed Teeth

- 50.4% reported never having had ET
- 21.5% reported having had ET 1×
- 28.0% reported having had ET ≥2×



Final multivariable regression models indicated that among participants with ≥ 25 teeth, those reporting having had ET $\geq 2\times$ had $1.62\times$ (95% confidence interval [CI], 1.04–2.53) the odds of prevalent CHD, compared with those reporting never having had ET (Table 1). Of the participants with ≤ 24 teeth, no significant differences in CHD prevalence were observed among groups regardless of their history of ET.

Conclusion

Of the ARIC study participants with ≥ 25 teeth, those with a greater self-reported history of ET were more likely to have CHD than those reporting no history of ET. Of the participants with ≤ 24 teeth, no significant differences between subgroups was observed. It is therefore important that more accurate epidemiologic quantification of endodontic infection and inflammation be required before definitive conclusions can be made about potential relationships between endodontic disease and CHD.

Caplan DJ, Pankow JS, Cai J, et al. The relationship between self-reported history of endodontic therapy and coronary heart disease in the Atherosclerosis Risk in Communities Study. *J Am Dent Assoc* 2009;140:1004-1012.

Chlorhexidine Gluconate for Intracanal Healing

Apical periodontitis is an inflammatory disease process resulting from infection of the root-canal space of the affected tooth. Apical periodontitis is healed through endodontic treatment geared toward eliminating the root-canal infection. Various regimens are routinely used to eradicate root-canal bacteria in teeth with apical periodontitis; the efficacy of these regimens is assessed by bacterial cultures taken from the root canals.

Complete healing of teeth with apical periodontitis ranges from 73% to 86%. However, in a recent study, 90% of 78 single-rooted teeth with apical periodontitis were healed after 4–6 years. The majority of these teeth were treated in 2 sessions, with calcium hydroxide ($\text{Ca}[\text{OH}]_2$).

Results with $\text{Ca}(\text{OH})_2$ have varied, however, leading to the suggestion that chlorhexidine gluconate (CHX) be used as an alternative intracanal medicament. While CHX is a potential intracanal medicament, data on

healing after its use are lacking. CHX is believed to cross the bacterial cell wall or outer membrane and attack the bacterial cytoplasmic or inner membrane. While CHX is bacteriostatic at low concentration, at high concentration it induces precipitation or coagulation of intracellular constituents, resulting in a bactericidal effect. CHX may also adsorb onto dental tissues and impart a substantive antimicrobial activity.

Tervit et al from the University of Toronto, Ontario, assessed the radiographic and clinical healing of teeth previously treated with CHX as an intracanal medicament. In this study, the canals of 22 teeth were instrumented and medicated with 2% CHX liquid for 7–15 days and subsequently filled. Bacterial samples were taken before and after instrumentation, after medication and before root filling, and evaluated by culture and vital microscopy.

After 26–53 months, 17 patients returned for follow-up (1 patient was deceased, 2 had had teeth extracted and 2 did not respond) and were clinically and radiographically analyzed, assigning Periapical Index (PAI) scores. Outcome was dichotomized as healed or as having post-treatment disease.

Sixteen of the 17 examined teeth (94%) were healed. With the 2 extracted teeth counted and considered to have a failed outcome, a total of 16 of 19 teeth (84%) healed. The proportion of healed teeth in this study did not differ significantly from that of a historical control in which $\text{Ca}(\text{OH})_2$ was the inter-appointment medication.

Table 1. Relationship between self-reported history of ET and prevalence of CHD, according to different reference categories*

	History of ET (odds ratio [95% CI])		
	Group 0: 0 ET	Group 1: 1 ET	Group 2: ≥ 2 ET
≤ 24 teeth	1.55 (1.05–2.30) [†]	1.04 (0.62–1.73)	1.74 (1.12–2.69) [†]
≥ 25 teeth	Reference	1.37 (0.83–2.26)	1.62 (1.04–2.53) [†]
≤ 24 teeth	Reference	0.67 (0.41–1.09)	1.12 (0.74–1.70)
≥ 25 teeth	0.64 (0.43–0.95) [†]	0.88 (0.54–1.46)	1.04 (0.66–1.64)

*From final multivariable logistic regression model; [†] $p < .05$.

Conclusion

With 94% single-rooted teeth with apical periodontitis assessed as healed 2–4 years after endodontic treatment, the results suggested comparable outcomes after root-canal medication with 2% CHX liquid or with interappointment $\text{Ca}(\text{OH})_2$. The authors cautioned that the results should not be generalized because the sample size was small.

Tervit C, Paquette L, Torneck CD, et al. Proportion of healed teeth with apical periodontitis medicated with two percent chlorhexidine gluconate liquid: a case-series study. *J Endod* 2009;35:1182-1185.

Calcium Hydroxide And pH Levels on Root Surfaces

Calcium hydroxide ($\text{Ca}(\text{OH})_2$) has been shown to arrest the inflammatory resorptive process in traumatized teeth. Root-canal debridement and placement of $\text{Ca}(\text{OH})_2$ into the canal space can elevate the dentinal tubule pH, thereby inhibiting osteoclastic activity, and create a favorable environment for repair with cementum. However, for $\text{Ca}(\text{OH})_2$ to be effective, the hydroxyl ions need to diffuse into the dentin and thus raise the pH level.

To test the null hypothesis that there is no difference in the pH on the external apical root surface when the canal is completely filled with $\text{Ca}(\text{OH})_2$ or when it is placed 3 or 5 mm short of the apical foramen in extracted human teeth, Chamberlain et al from Wilford Hall Medical Center, Texas, studied 40 extracted teeth. These human permanent maxillary and mandibular anterior single-rooted teeth

were decoronated 10 mm from the apex to create roots of equal length. All teeth were then instrumented using a crown-down technique.

A round bur was used to make cavities on the external root surface measuring 0.50 mm deep by 1.0 mm in diameter at 1, 3 and 5 mm coronal to the apical foramen. The teeth were then randomly assigned to 4 groups:

- Group A (n = 10) was filled 1 mm short of the apical foramen
- Group B (n = 10) was filled 3 mm short of the apical foramen
- Group C (n = 10) was filled 5 mm short of the apical foramen
- Group D (n = 10) was left empty

The $\text{Ca}(\text{OH})_2$ was placed into the root canals using a NaviTip (UltraDent Products, Inc., South Jordan, Utah) at 1, 3 or 5 mm from the apical foramen. Proper placement of $\text{Ca}(\text{OH})_2$ was verified by digital radiographs. The pH was then measured in the cavities immediately after placement of the $\text{Ca}(\text{OH})_2$, and at 1, 3, 5, 7, 14, 21 and 28 days.

There was an increase in the pH of the experimental cavities of groups A and B over that of the control cavities of group D over the first 14 days, and then a gradual return to the average pH level of the control group D at days 21 and 28. The roots filled within 1 mm of the radiographic apex had the greatest increase in pH in each of the cavities (Figure 1).

Conclusion

The results of this study demonstrated that the pH in the experimental cavities increased significantly as the canals were more completely filled with $\text{Ca}(\text{OH})_2$. Thus, the beneficial effects of $\text{Ca}(\text{OH})_2$ appear to be related not

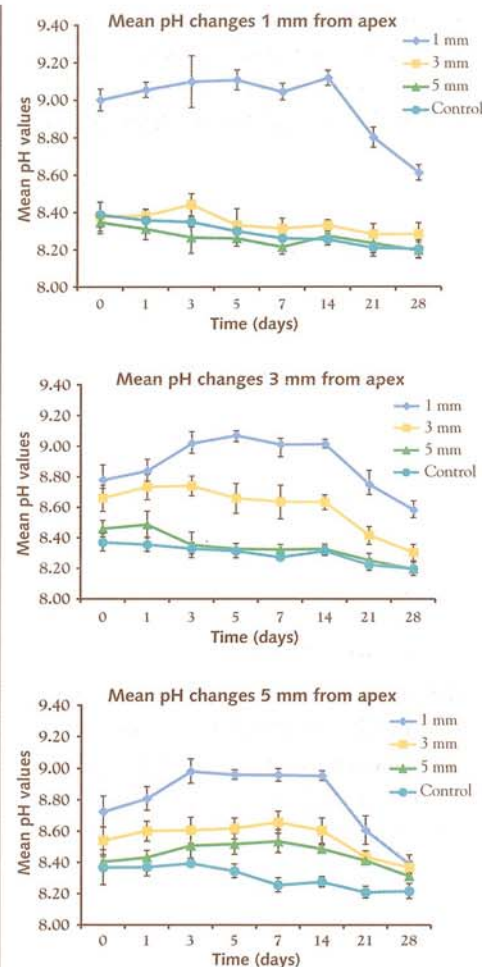
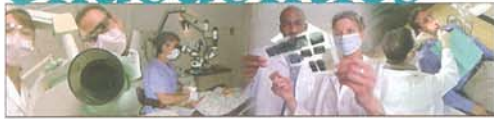

Figure 1. Pattern of pH changes at 1, 3 and 5 mm from the apex. At 1 mm, pH levels measured in group A were significantly different from the pH levels in all other groups ($p < .001$). At 3 mm, pH levels measured in group A were significantly different from pH levels in all other groups ($p < .001$), and pH levels in group B were significantly different from groups C and D. At 5 mm, pH levels measured in group A were significantly different from the pH levels in all other groups ($p < .001$).

only to time but also to the placement of $\text{Ca}(\text{OH})_2$ to within 1 mm of the radiographic apex.

Chamberlain TM, Kirkpatrick TC, Rutledge RE. pH changes in external root surface cavities after calcium hydroxide is placed at 1, 3 and 5 mm short of the radiographic apex. *Dent Traumatol* 2009;25:470-474.



Splinting Times for Replanted Avulsed Teeth

Tooth avulsion is defined as complete displacement of a tooth from its alveolar socket. As a result of this injury, the pulpal blood supply and nerves are severed at the root apex, and the cells of the periodontal ligament are exposed to the external environment.

If the tooth is replanted promptly, functional periodontal healing can occur. The extraoral period significantly affects the outcome, influencing periodontal ligament (PDL) vitality. The longer the tooth is out of the socket, the likelihood of PDL cell death increases, as does the incidence of unfavorable healing.

Clinical guidelines are valuable in assisting clinicians to deliver the most up-to-date care possible. Current trauma management aims to prevent or minimize inflammation from PDL cell damage and/or pulpal infection. Hinckfuss and Messer from the University of Melbourne, Australia, conducted a systematic review of the literature to examine evidence on splinting duration and periodontal healing outcomes.

Splinting stabilizes an avulsed tooth, allowing for potential pulpal and periodontal healing. Lack of splinting increases the risk of further trauma and instability during healing. Ideally, a splint should stabilize the tooth in the original position without causing additional trauma, orthodontic forces or gingival injury, and allow for adequate oral hygiene. Semi-rigid or flexible splinting allows for physiologic

tooth movement, which has been shown to assist healing.

A previous review of the literature indicated that splint type was not generally a significant variable influencing healing outcomes. The effect of splinting duration on periodontal healing has not been clarified in clinical studies to date.

Long-term splinting has been linked with ankylosis, a fusion of bone to root structure, and replacement resorption. Ankylosis is the most commonly reported periodontal outcome after replantation. Significantly improved outcomes with short-term splinting, however, have not been shown. The current guidelines for management of avulsed permanent teeth recommend splinting periods as follows:

- International Association of Dental Traumatology (IADT), ≤2 weeks
- American Academy of Pediatric Dentistry, 7 days
- American Academy of Endodontics, 7–14 days
- Royal College of Dental Surgeons England, 7–10 days

Recommended splint types include

- acid-etch bonded composite resin splints (e.g., wire-composite)
- titanium trauma splints

The IADT guidelines are updated regularly.

After performing a search across several databases, the authors included 4 retrospective studies and 4 prospective studies in their review. When the authors focused their qualitative systematic review on splinting duration

(≤14 days, >14 days), the evidence showed an association between short-term splinting, while an increased likelihood of functional periodontal healing, acceptable healing, or decreased development of replacement resorption appeared inconclusive.

Conclusion

This review found no evidence to contradict the current guidelines and suggested that the likelihood of successful periodontal healing after replantation is unaffected by splinting duration. Pending future evidence to the contrary, dentists should continue to use the currently recommended splinting periods of 7–14 days when replanting avulsed permanent teeth.

Hinckfuss SE, Messer LB. Splinting duration and periodontal outcomes for replanted avulsed teeth: a systematic review. Dent Traumatol 2009;25:150-157.

In the next issue

- Eradication of biofilm by cetrimide and chlorhexidine
- Histology of regenerated tissue in canal space
- Postoperative pain after endodontic procedures

*Do you or your staff have any questions or comments about **Update on Endodontics**? Please call or write our office. We would be happy to hear from you.* ©2010